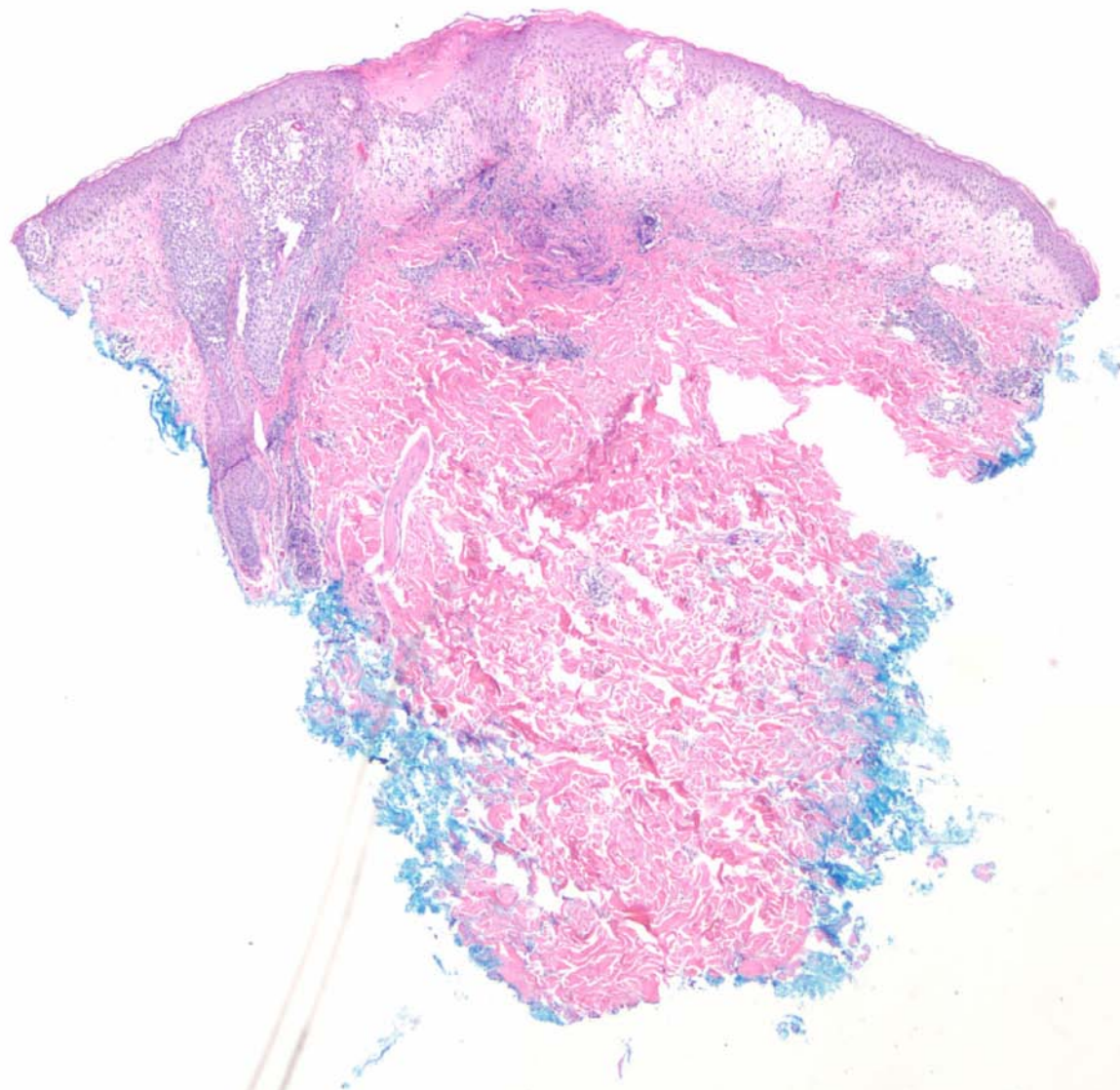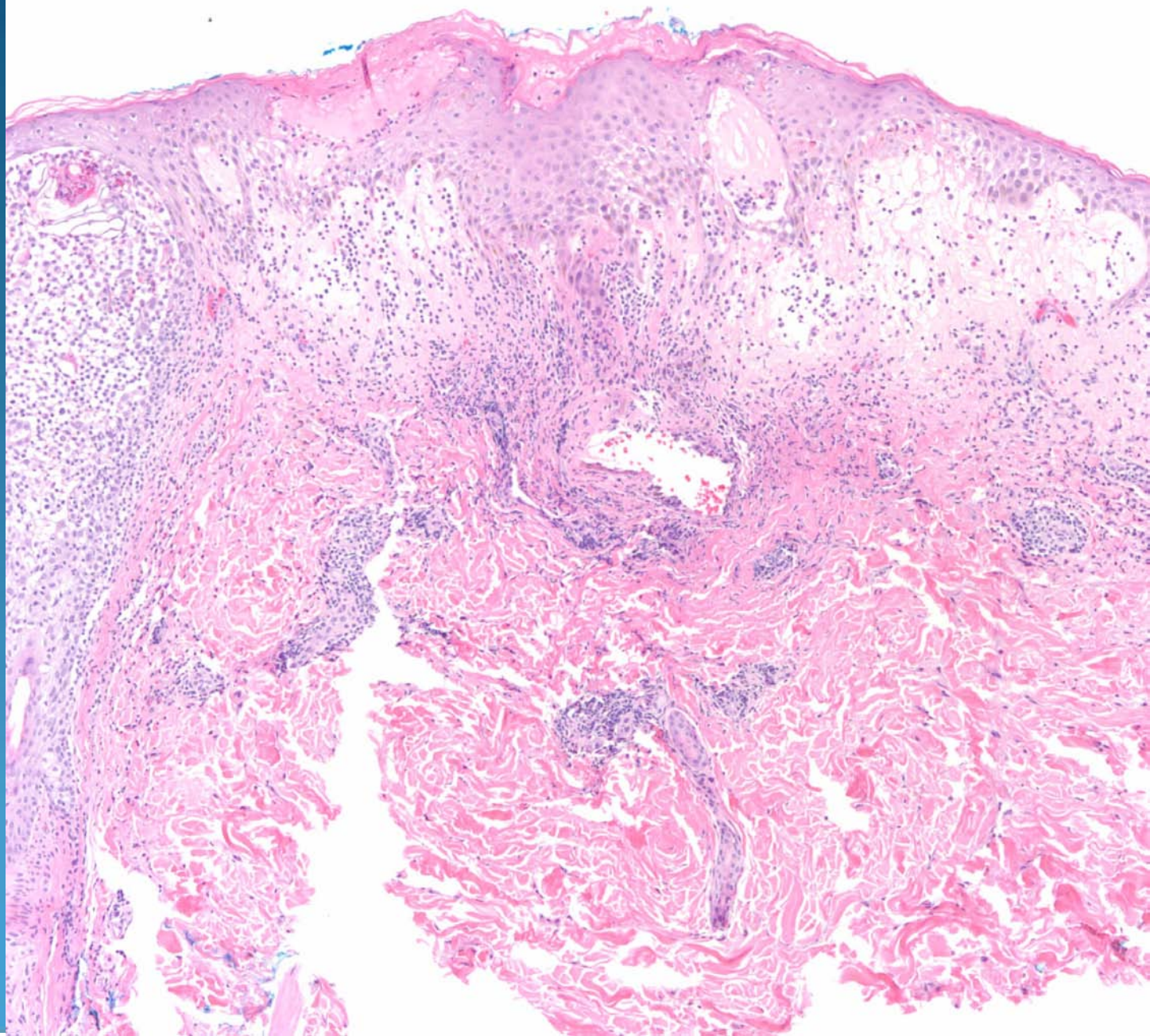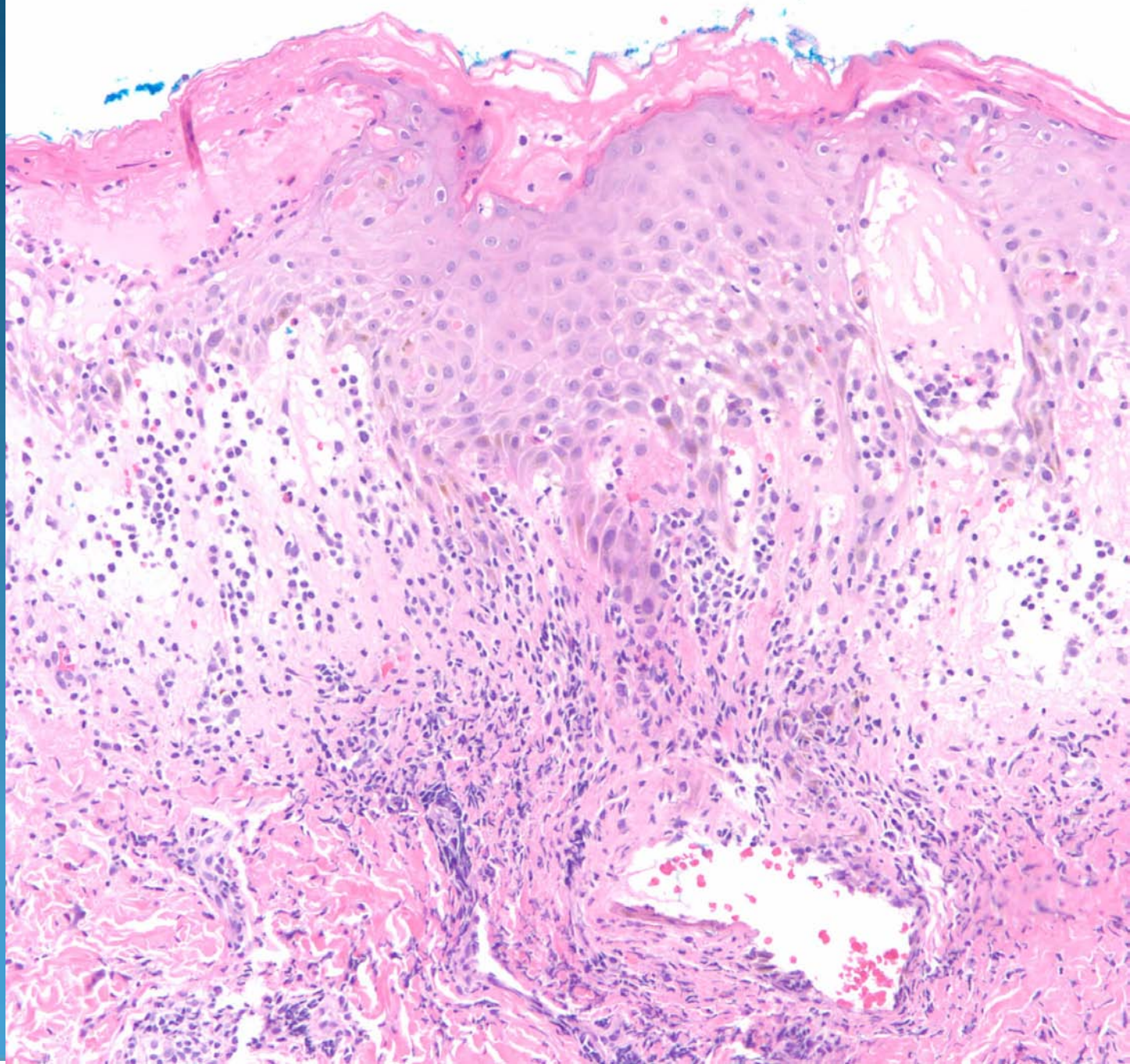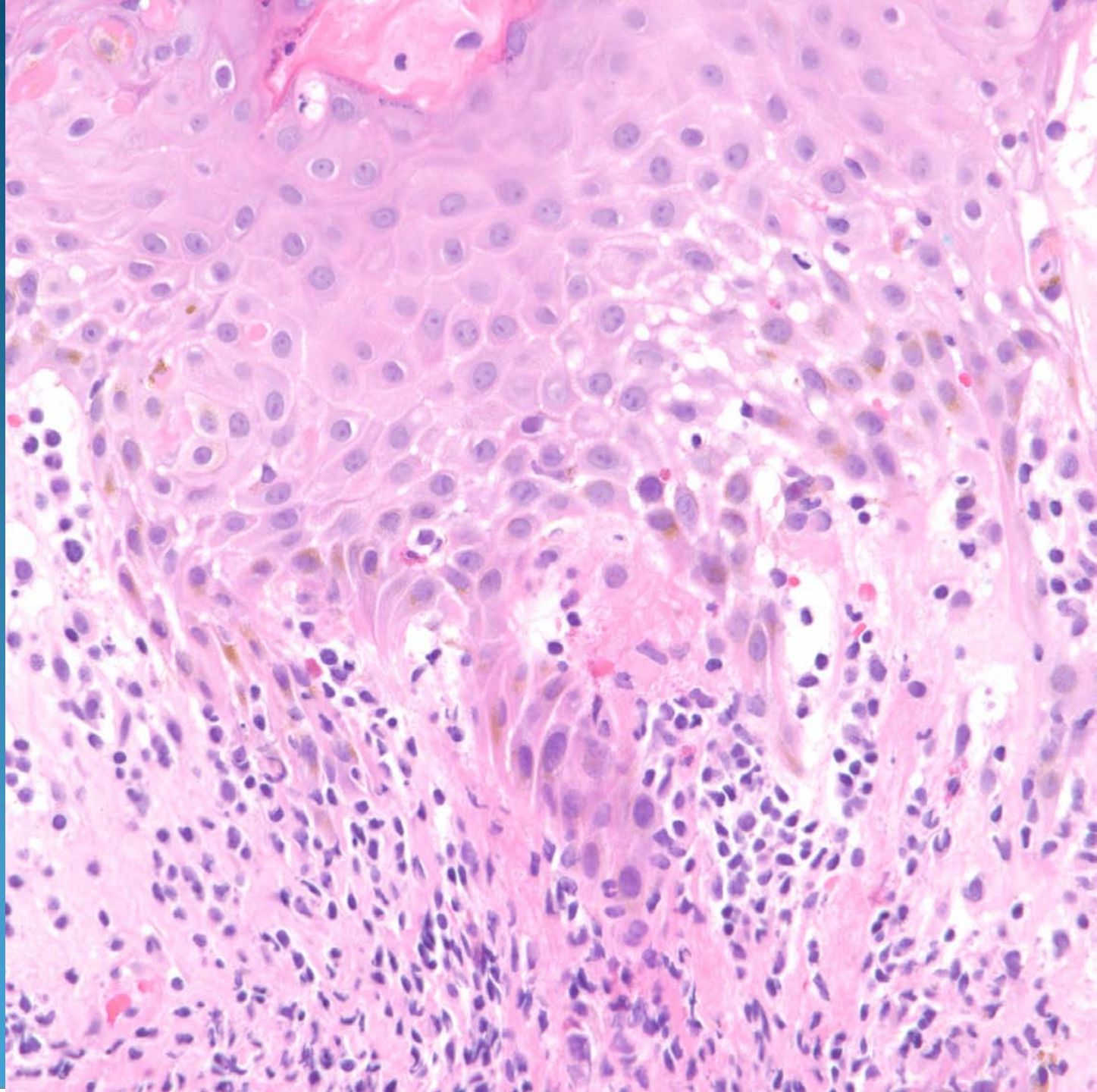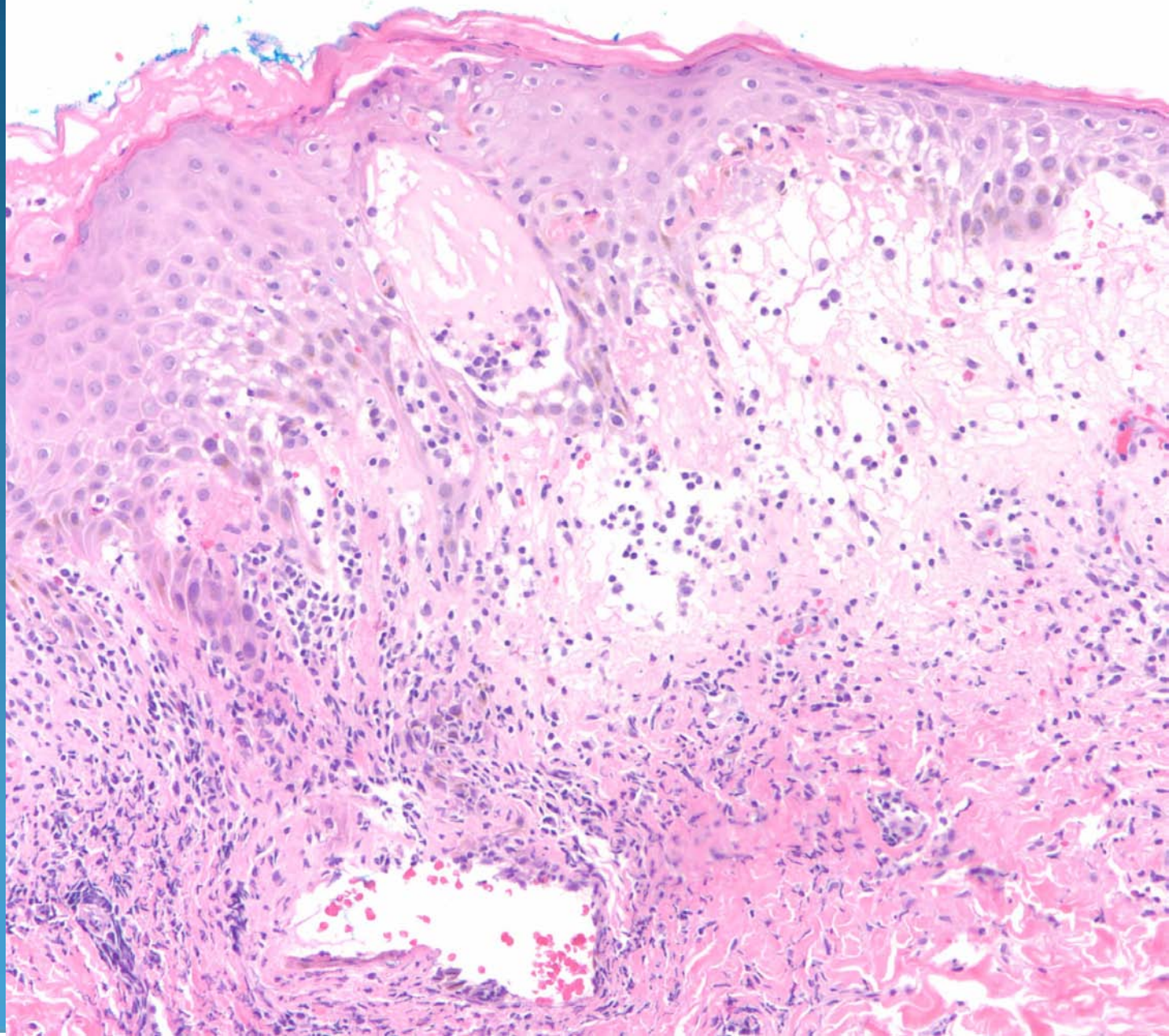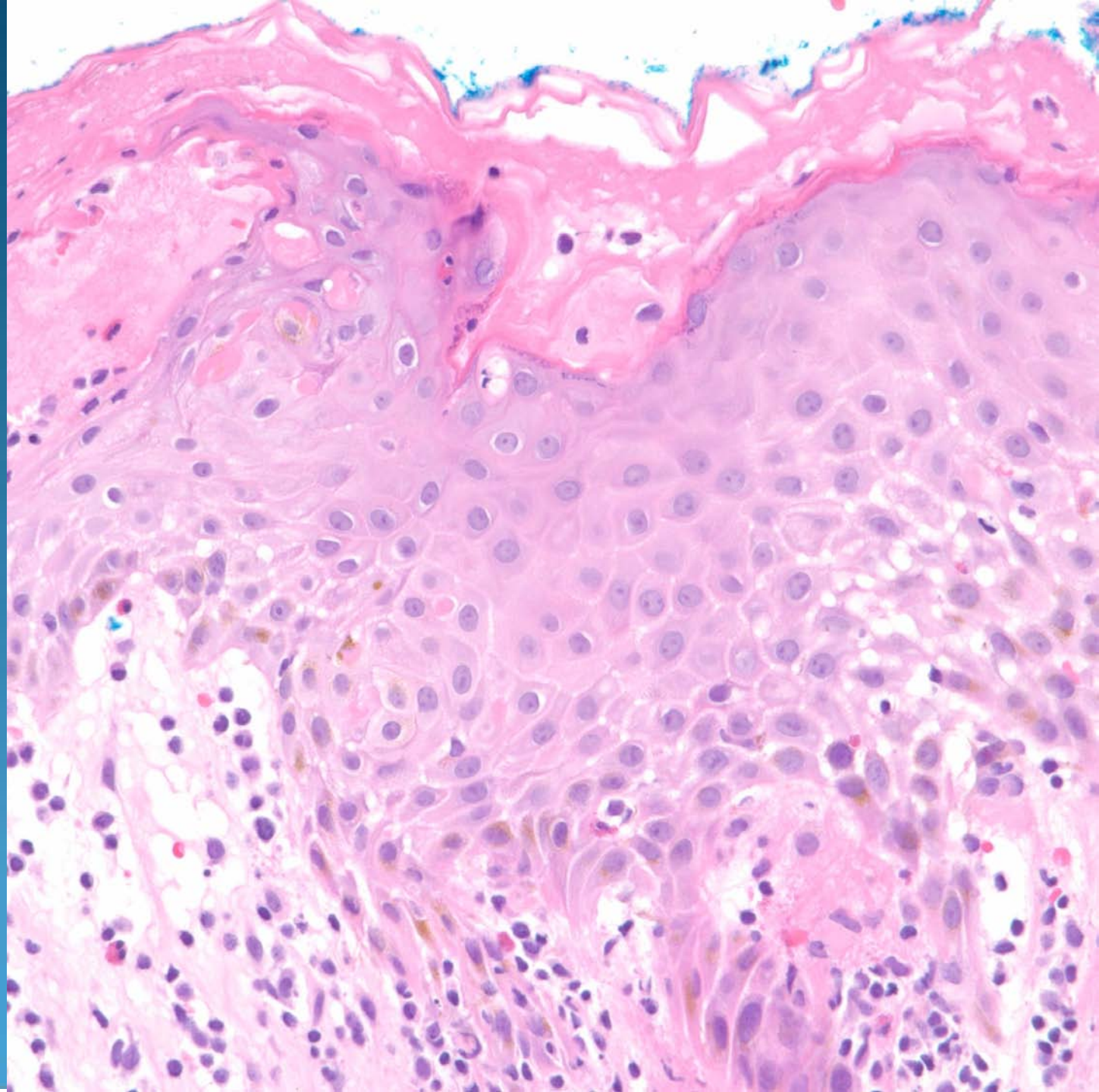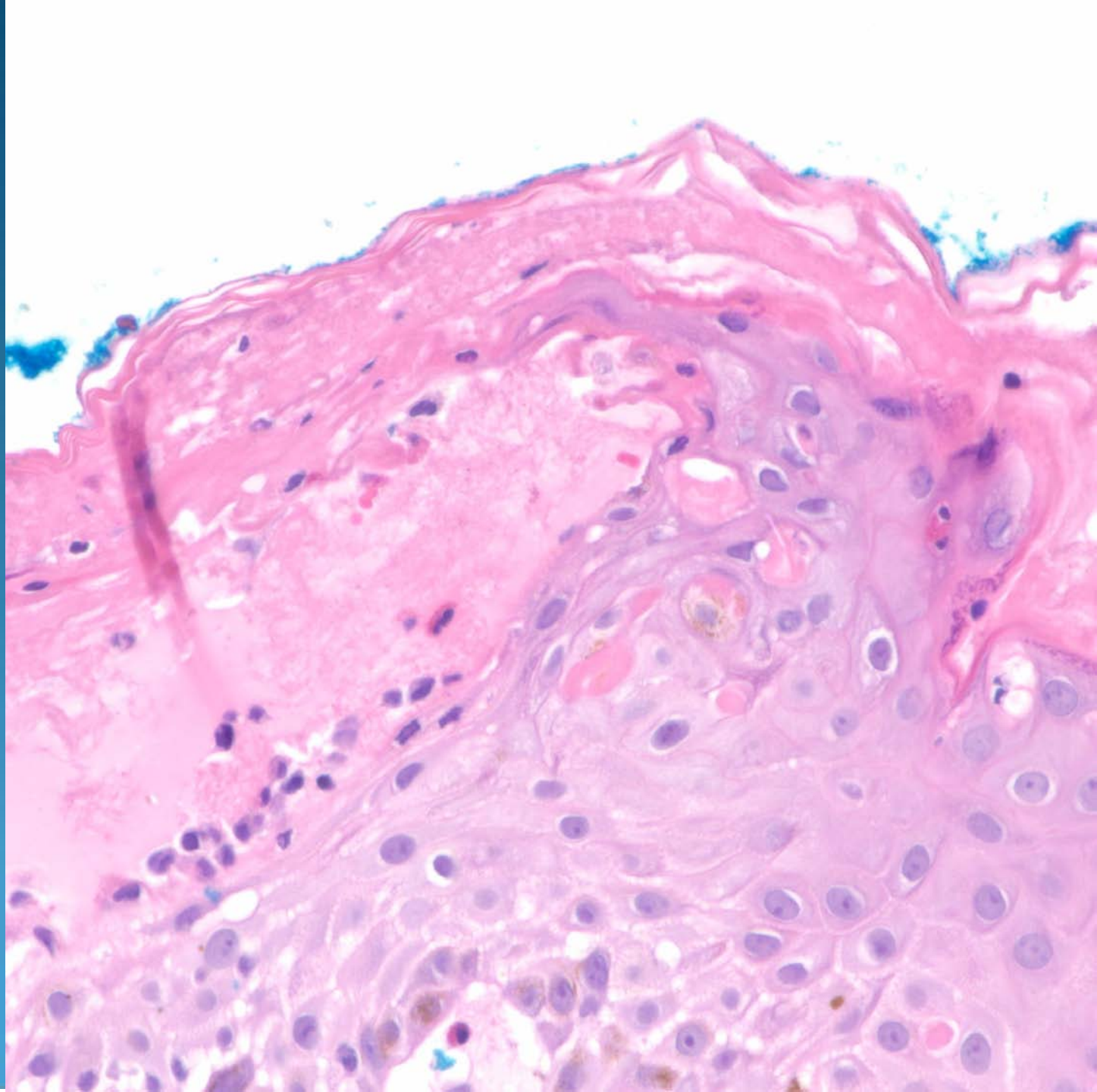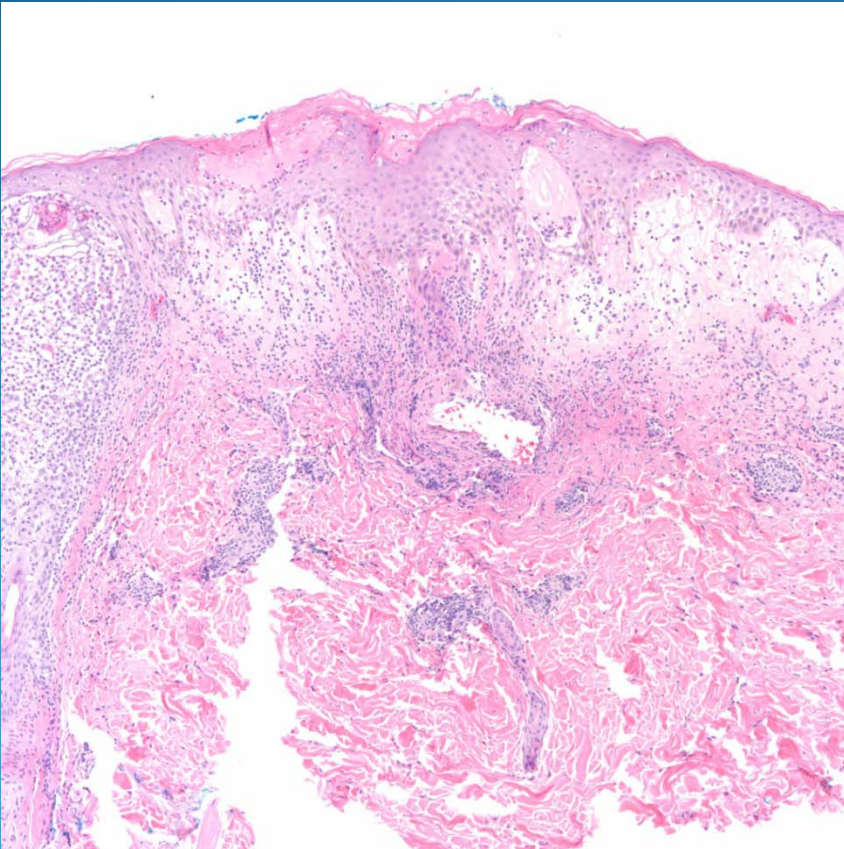


Allergic Contact Dermatitis

Pearls



- Spongiotic dermatitis with eosinophils with variable vesicular stage depending upon stage and severity of insult
- Eosinophils
- Scattered dyskeratotic cells
- Rule out other hypersensitivity reaction